

## SHORT REPORT

# Recognising signs of danger: ECG changes resulting from an abnormal serum potassium concentration

A Webster, W Brady, F Morris

*Emerg Med J* 2002;**19**:74–77

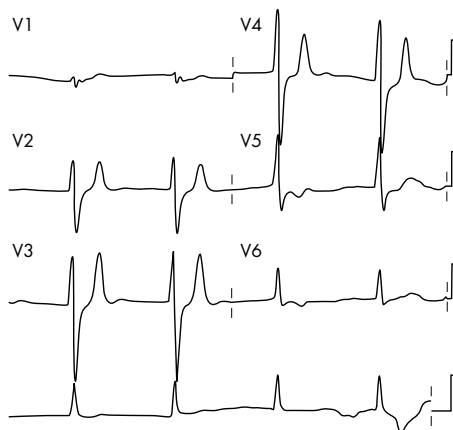
A number of metabolic insults can result in changes to the serum potassium concentration. Potassium is predominantly an intracellular cation, and it has an important role in determining the resting membrane potential of cells. Disruption of the potassium gradient across the cell membrane can result in impaired cellular functioning. This may affect a number of organs including the cardiovascular and central nervous systems, resulting in various neurological symptoms and cardiac arrhythmias.

Though laboratory tests are the gold standard test for diagnosing changes in the serum electrolyte concentration, there may be delays in obtaining the results. The electrocardiogram (ECG) may be a useful diagnostic tool, if the clinician is aware of the possible changes resulting from abnormalities in the serum potassium concentration. This article presents three cases that highlight the ECG changes resulting from an abnormal serum potassium concentration and will briefly look at the treatment options to reduce the risk of life threatening arrhythmias occurring.

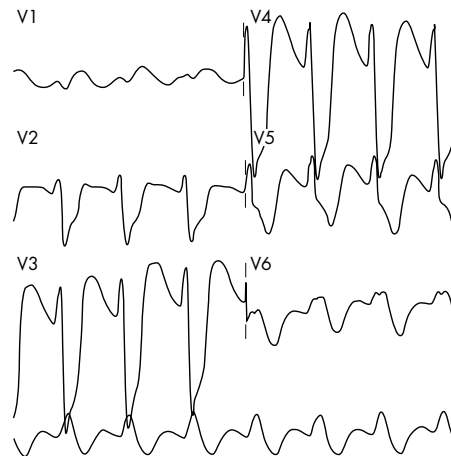
## CASE REPORTS

### Case 1

A 63 year old Asian woman with type II insulin treated diabetes and end stage renal failure, receiving three times weekly haemodialysis, was brought to the accident and emergency (A&E) department with a 24 hour history of worsening nausea and vomiting. She had missed a dialysis session when taking a short holiday to visit relatives in Pakistan. On examination she was 98% saturated on 2 l/min oxygen, there were a few scattered inspiratory crackles, and some mild lower limb pitting oedema.



**Figure 1** Moderate hyperkalaemia in a patient who had missed a dialysis session (case 1). The ECG abnormalities are an absence of the p-wave, nodal rhythm. Widened QRS complex. Peaked T-waves V3-V4. This ECG tracing would be compatible with moderate hyperkalaemia.



**Figure 2** Severe hyperkalaemia in a patient with iatrogenic renal failure (case 2). The ECG abnormalities noted are absence of the P-wave. Extremely bizarre widened QRS complexes, Sine wave in appearance.

An electrocardiogram (ECG) was recorded that showed peaked T-waves in the anterior leads, loss of P-waves, with slight prolongation of the QRS interval (fig 1). A set of laboratory investigations were requested that showed a sodium level of 134 mmol/l, potassium 7.6 mmol/l, bicarbonate 17 mmol/l, urea 40 mmol/l, and a creatinine of 757 mmol/l.

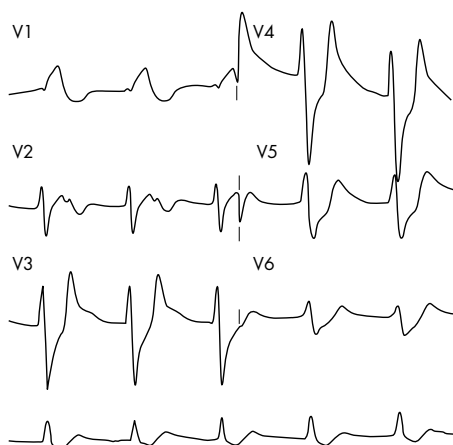
The patient was treated with 10 units of actrapid and 50 ml of 50% dextrose intravenously. She was transferred to the renal services where urgent haemodialysis was organised.

### Case 2

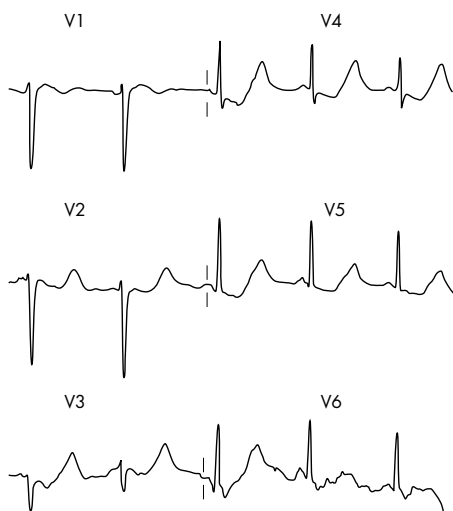An 83 year old man was brought to A&E in extremis from a local nursing home. He had been increasingly unwell over the preceding five days with worsening orthopnoea and peripheral oedema. He had developed severe shortness of breath a few hours before admission. A detailed history was not available. On examining his drug regimen, his current treatments were found to consist of 80 mg frusemide, 20 mg lisinopril, and 125 µg of digoxin. In addition he had received a five day course of diclofenac for an acute episode of gout 10 days earlier. On examination he was moribund with an oxygen saturation of 78% on 15 l/min oxygen via facemask. Pulse 145/min irregular, an audible 3rd heart sound, a respiratory rate of 50/min, inspiratory crackles were heard throughout both lung fields. There was three finger palpable hepatomegaly, and marked sacral and pretibial oedema.

An ECG was recorded that showed absence of P-waves and broad bizarre QRS complexes (fig 2). Blood was taken when

**Abbreviations:** ECG, electrocardiogram



**Figure 3** The patient with renal failure after treatment of his hyperkalaemia (case 2). The ECG changes seen now are the still absent P-waves. QRS complexes less broad. T-waves have a more tented appearance.



**Figure 4** Hypokalaemia in a girl with anorexia nervosa and purgative abuse (case 3). Sinus rhythm. Normal axis. Narrow QRS complex. ST depression V3-V5. "Apparent" prolonged QT interval. T-waves unseparable from giant U-waves seen V2-6.

intravenous access was obtained. Treatment consisted of immediate administration of 20 ml 10% calcium chloride solution, 10 units of actrapid, and 50 ml of 50% dextrose for presumed hyperkalaemia; 100 mg of frusemide, and IV nitrates were given to treat the pulmonary oedema. A repeat ECG demonstrated a slightly less broad QRS complex, tall tented T-waves and a nodal rhythm (fig 3). His biochemistry was telephoned back, which confirmed the initial diagnosis

made on ECG of hyperkalaemia. His potassium had initially been 9.3 mmol/l, urea 50 mmol/l, creatinine 800 mmol/l, and serum bicarbonate 8 mmol/l. There was some resolving of the ECG signs, but his clinical condition deteriorated, and despite full resuscitative treatment the patient died.

### Case 3

A 17 year old girl who was known to suffer with anorexia nervosa, and purgative misuse, was taken to the local A&E department by her parents because she complained she had felt so weak, and had not been able to get out of bed.

On examination apart from marked weight loss, nothing of significance was detected. Among with other initial tests an ECG was recorded (fig 4).

It was recognised that the ECG was not normal, with ST depression in leads V3-6, and what was thought a prolonged QT interval. Biochemistry phoned her blood tests back urgently confirming the diagnosis of hypokalaemia, her potassium being 1.8 mmol/l.

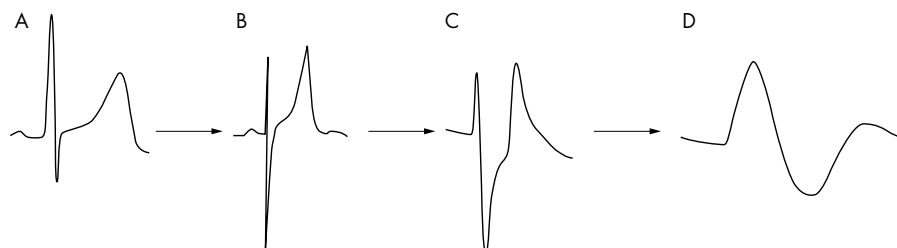
When the ECG was re-examined, it was recognised that the prolonged QT interval was in fact a QU interval, the T-waves were actually giant U-waves.

An IV infusion of normal saline with potassium supplementation was started and the patient was referred to the medical on call team.

### DISCUSSION

These three short cases illustrate the effects that changes in the serum potassium can have on the ECG. They also show that the ECG can be a useful early diagnostic tool, which may help the emergency physician start lifesaving treatment while awaiting confirmatory biochemical tests.

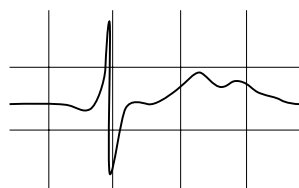
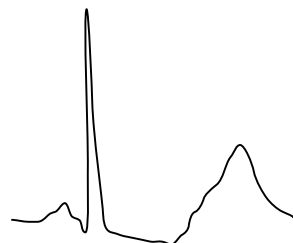
The first two cases demonstrated the most common changes associated with hyperkalaemia of (1) tall peaked T-waves (2) reduction in amplitude and eventually loss of the P-wave and (3) bizarre widening of the QRS interval (table 1, fig 5 B-D). These ECG changes can be explained by the electrolytes physiological effect on myocardial cells. Mild levels of hyperkalaemia are associated with acceleration of terminal repolarisation, resulting in T-wave changes. The most common changes seen in the T-waves are "tenting" or "peaking" (case 1, fig 1, 5B), they are considered to be the earliest abnormalities seen in the ECG. Mild to moderate hyperkalaemia causes depression of conduction between adjacent cardiac myocytes, this results in prolongation of the PR and QRS intervals as potassium levels rise. P-wave amplitude disappears early because of the sensitivity of atrial myocytes to hyperkalaemia (case 2, fig 2, fig 5C). As the severity of hyperkalaemia increases, there is further suppression of sinoatrial and atrioventricular conduction, resulting in the appearance of escape beats and escape rhythms.<sup>1 2</sup> The QRS complex will continue to widen and may blend with the T-wave, creating a sine-wave appearance to the ECG (fig 5D). If the potassium level is allowed to rise without treatment, ventricular fibrillation will result.<sup>1</sup>



**Figure 5** The ECG changes as hyperkalaemia develops. (A) A normal complex. (B) Loss of P-waves, tenting of the T-waves. (C) Broadening of the QRS complex. (D) Sine wave appearance.

**Table 1** Electrocardiographic manifestations of serum hyperkalaemia relative to serum potassium level

Serum potassium level	Expected ECG abnormality
Mild hyperkalaemia 5.5–6.5 mmol/l	Tall, peaked T-waves with narrow base
Moderate hyperkalaemia 6.5–8.0 mmol/l	Peaked T-waves Prolonged PR interval Decreased amplitude of P-waves Widening of QRS complex
Severe hyperkalaemia >8.0 mmol/l	Absence of P-wave Progressive widening of QRS complex Eventual "sine-wave" pattern, VF, asystole

**Figure 6** The appearance of U-waves in hypokalaemia.**Figure 7** Giant U-waves.

These classic ECG changes, which have been well described in the literature, are not always present.<sup>3–5</sup> The relation between ECG changes and serum potassium will vary between people. It is therefore important to realise that the ECG is not always a reliable test for mild to moderate hyperkalaemia.<sup>4</sup> Even in severe hyperkalaemia, only minimal changes may be seen on the ECG.<sup>3</sup>

In addition to the classic ECG manifestations there have been other ECG changes resulting from hyperkalaemia reported in the literature. These include complete heart block, trifascicular block and QRS axis shift.<sup>1–6,7</sup> Hyperkalaemia may also produce ECG changes that mimic acute myocardial infarction.<sup>8</sup> This is of particular importance to the emergency physician as it may result in the administration of inappropriate treatment such as thrombolysis. The changes mimicking infarction or ischaemia will resolve with the treatment of hyperkalaemia.

The management of hyperkalaemia was well covered in a recent review,<sup>9</sup> but basically consists of four steps (1) Determine and treat any reversible causes. (2) Measures to reduce membrane excitability for example with calcium chloride intravenously. (3) Therapeutic measures to reduce serum potassium, initially with intravenous 50% dextrose and insulin. Salbutamol can then be administered either by the nebulised or intravenous route. Sodium bicarbonate can be useful especially in an acidotic patient. (4) Haemodialysis, which is the definitive measure to reduce serum potassium.

The third case demonstrated the effects of hypokalaemia on the ECG (fig 4). Hypokalaemia is a relatively common biochemical abnormality found on routine screening in the A&E department. There are many causes including diarrhoea and vomiting, inappropriate fluid replacement and drugs, such as loop and thiazide diuretics. In addition to the biochemical diagnosis, the emergency physician should be aware of the ECG manifestations that may result from hypokalaemia.

The effect of hypokalaemia on the cell membrane is to increase the resting membrane potential, and increase the duration of the action potential and refractory period, which are potentially arrhythmogenic.<sup>10</sup> The classic ECG changes described are (1) a reduction in the T-wave amplitude. (2) depression of the ST-segment. (3) U-waves that are an unknown entity, usually seen as a small positive deflection after the T-wave best seen in leads V2, V3 (fig 6).

In severe hypokalaemia giant U-waves have been described that can be mistaken for peaked T-waves.<sup>12</sup> To differentiate

between peaked T-waves and giant U-waves the following rules can be used to aid the diagnosis. The peaked T-waves in hyperkalaemia tend to have a narrow base, tall with a prominent peak, the QT interval is normal or decreased. U-waves tend to be broad based and there may be an apparent prolongation of the QT interval, which is really a QU interval (figs 5B, 7).

In addition to these ECG manifestations, hypokalaemia has been shown to increase the risk of various malignant ventricular arrhythmias. A Swedish study demonstrated the increased risk of ventricular tachycardia postmyocardial infarction in patients with hypokalaemia.<sup>13</sup> Other arrhythmias described include ventricular ectopic beats, and ventricular fibrillation.<sup>10</sup>

A slightly reduced serum potassium level without ECG changes can simply be treated with oral supplementation. Profound or life threatening hypokalaemia should be treated with intravenous potassium replacement, with regular monitoring of the serum potassium level.<sup>14</sup>

## CONCLUSIONS

- Changes in serum potassium concentrations may cause life threatening arrhythmias.
- An alert physician recognising the ECG changes, may be able to provide lifesaving treatment before receiving biochemical confirmation.
- Hyperkalaemia is treated by first stabilising the cardiac membrane then by reducing the serum potassium concentration.
- Hypokalaemia is treated by potassium replacement, the urgency and route depends on ECG changes and serum level.

## ACKNOWLEDGEMENTS

Contributors: AW participated in carrying out the literature search, and in writing the paper. WB participated in carrying out the literature search, and in writing the paper. FM initiated the original idea for the paper, supplied the clinical material, edited the paper, and acts as guarantor.

Funding: none.

Conflicts of interest: none.

.....

#### Authors' affiliations

**A Webster**, Addenbrooke's NHS Trust, Cambridge, UK  
**W Brady**, University of Virginia School of Medicine, Charlottesville, Virginia, USA  
**F Morris**, Northern General Hospital, Sheffield, UK

Correspondence to: Mr F Morris, Department of Accident and Emergency, Northern General Hospital, Herries Road, Sheffield S5 7AU, UK; F.P.Morris@Sheffield.ac.uk

Accepted for publication 11 June 2001

#### REFERENCES

- Przybojewski JZ**, Knott-Craig CJ. Hyperkalaemic complete heart block. A report of 2 unique cases and a review of the literature. *S Afr Med J* 1983;**63**:413–20.
- Pick A**. Arrhythmias and potassium in man. *Am Heart J* 1966;**72**:295–306.
- Yu AS**. Atypical electrocardiographic changes in severe hyperkalaemia. *Am J Cardiol* 1996;**77**:906–8.
- Wrenn KD**, Slovis CM, Slovis BS. The ability of physicians to predict hyperkalaemia from the ECG. *Ann Emerg Med* 1991;**20**:1229–32.
- Martinez-Vea A**, Bardaji A, Garcia C. Severe hyperkalaemia with minimal electrocardiographic manifestations: a report of seven cases. *J Electrocardiol* 1999;**32**:45–9.
- Lichstein E**, Gupta PK, Grunwald AA. Hyperkalaemic fascicular block. *Chest* 1976;**70**:290–1.
- Ewy GA**, Karliner J, Bedynek JL Jr. Electrocardiographic QRS axis shift as a manifestation of hyperkalaemia. *JAMA* 1971;**215**:429–32.
- Chawla KK**, Cruz J, Kramer NE, *et al*. Electrocardiographic changes simulating acute myocardial infarction caused by hyperkalaemia: report of a patient with normal coronary arteriograms. *Am Heart J* 1978;**95**:637–40.
- Ahee P**, Crowe A. The management of hyperkalaemia in the emergency department. *J Accid Emerg Med* 2000;**17**:188–91.
- Helfant RH**. Hypokalaemia and arrhythmias. *Am J Med* 1986;**80** (suppl 4A):13–22.
- Weaver WF**, Burchel H. Serum potassium and the electrocardiogram and hypokalaemia. *Circulation* 1973;**47**:408–18.
- Reddy GV**, Schamroth I, Schamroth CL. Tall and peaked U waves in hypokalaemia. *Chest* 1987;**91**:605–7.
- Nordrehaug JE**, Johannessen KA, Von der Lippe G. Serum potassium concentration as a risk factor of ventricular arrhythmias early in acute myocardial infarction. *Circulation* 1985;**71**:645–9.
- Souhami RL**, Moxham J. *Textbook of medicine*. 3rd edn. 1997.



## Recognising signs of danger: ECG changes resulting from an abnormal serum potassium concentration

A Webster, W Brady and F Morris

*Emerg Med J* 2002 19: 74-77

doi: 10.1136/emj.19.1.74

---

Updated information and services can be found at:

<http://emj.bmj.com/content/19/1/74.full.html>

---

*These include:*

### References

This article cites 13 articles, 6 of which can be accessed free at:

<http://emj.bmj.com/content/19/1/74.full.html#ref-list-1>

Article cited in:

<http://emj.bmj.com/content/19/1/74.full.html#related-urls>

### Email alerting service

Receive free email alerts when new articles cite this article. Sign up in the box at the top right corner of the online article.

---

### Notes

---

To request permissions go to:

<http://group.bmj.com/group/rights-licensing/permissions>

To order reprints go to:

<http://journals.bmj.com/cgi/reprintform>

To subscribe to BMJ go to:

<http://group.bmj.com/subscribe/>